



Official reprint from UpToDate®

www.uptodate.com © 2023 UpToDate, Inc. and/or its affiliates. All Rights Reserved.



Wolters Kluwer

# Ingested foreign bodies and food impactions in adults

**AUTHOR:** [George Triadafilopoulos, MD](#)**SECTION EDITOR:** [John R Saltzman, MD, FACP, FACG, FASGE, AGAF](#)**DEPUTY EDITOR:** [Shilpa Grover, MD, MPH, AGAF](#)

All topics are updated as new evidence becomes available and our [peer review process](#) is complete.

Literature review current through: **Sep 2023**.

This topic last updated: **Oct 11, 2023**.

## INTRODUCTION

Foreign body ingestion and food impactions are usually accidental in adults. This topic will review the approach to adults with ingested foreign bodies and food impactions. Our approach is largely consistent with the American Society for Gastrointestinal Endoscopy and European Society for Gastrointestinal Endoscopy guidelines [1,2].

The approach to foreign body ingestion in children and the conditions that predispose to foreign body or food bolus impaction are discussed separately. The approach to patients with internal concealment of drugs of abuse (body packing) is discussed in detail, separately. (See ["Foreign bodies of the esophagus and gastrointestinal tract in children"](#) and ["Esophageal rings and webs"](#) and ["Endoscopic interventions for nonmalignant esophageal strictures in adults"](#) and ["Achalasia: Pathogenesis, clinical manifestations, and diagnosis"](#) and ["Clinical manifestations, diagnosis, and staging of esophageal cancer"](#) and ["Zenker's diverticulum"](#) and ["Clinical manifestations and diagnosis of eosinophilic esophagitis \(EoE\)"](#).)

## EPIDEMIOLOGY

In adults, food (typically meat) bolus impaction above a pre-existing esophageal stricture, eosinophilic esophagitis, or Schatzki's ring is by far the most common cause of esophageal obstruction. Foreign body ingestion is rare in adults as compared with children [3]. Foreign body ingestion is accidental in 95 percent of cases and is usually related to food (eg, fish and

chicken bones, toothpicks) [4]. Foreign body ingestion in adults occur more frequently in older adults, in individuals with underlying psychiatric diseases or alcohol intoxication, in prison inmates, and for the purpose of drug trafficking [5-7]. Rarely, foreign body impaction occurs as a complication of pill ingestion [8,9]. (See "[Internal concealment of drugs of abuse \(body packing\)](#)", section on 'Epidemiology'.)

Most (80 to 90 percent) ingested foreign bodies pass without the need for intervention [10,11]. Endoscopic intervention is required in 10 to 20 percent of patients; the urgency for endoscopy depends on the underlying clinical scenario and the nature of impaction (food versus foreign body) [12]. In some cases, endoscopy can be avoided if a radiograph immediately prior to the procedure reveals that the foreign body has passed [13]. Surgical intervention is required in less than 1 percent [2,14].

The esophagus is the most frequent site of obstruction in the gastrointestinal tract. Esophageal foreign bodies are often impacted at sites of physiologic or pathologic luminal narrowing. Physiologic narrowing of the esophagus occurs at the upper esophageal sphincter, at the level of the aortic arch, and at the diaphragmatic hiatus. Structural or functional esophageal abnormalities that increase the risk of foreign body/food impaction in the esophagus include diverticula, webs, rings, strictures, achalasia, and tumors ( [table 1](#)) [15]. It is estimated that approximately half the individuals with esophageal food impactions have underlying eosinophilic esophagitis [16]. (See "[Clinical manifestations and diagnosis of eosinophilic esophagitis \(EoE\)](#)", section on 'Clinical manifestations'.)

---

## CLINICAL MANIFESTATIONS

**Symptoms** — The typical clinical presentation is the acute onset of dysphagia. Other symptoms of esophageal foreign body impaction include choking, refusal to eat, hypersalivation, retrosternal fullness, regurgitation of undigested food, wheezing, and blood-stained saliva. Odynophagia may be due to esophageal spasm but may also be indicative of an underlying infection, ulceration, or perforation. Drooling and inability to swallow liquids is indicative of an esophageal obstruction [1,17,18].

In the absence of a complication (eg, complete obstruction, perforation), the majority of patients are asymptomatic once the foreign body has passed the esophagus but a sensation of foreign body, with dysphagia, can persist for several hours and thus can mimic a persisting foreign body impaction [19-22].

**Complications** — Complications of foreign body ingestion include perforation, complete obstruction with pulmonary aspiration, aortoesophageal fistula formation, and tracheoesophageal fistula formation [23-27]. These complications are rare with food bolus impaction.

**Perforation** — Patients with cervical perforations can present with neck pain, dysphagia, odynophagia, or dysphonia. Patients may have tenderness to palpation of the sternocleidomastoid muscle and crepitation due to the presence of cervical subcutaneous emphysema. Perforation in the oropharynx or proximal esophagus can cause neck swelling, tenderness, erythema, or cervical crepitus. Patients with a perforation in the mid or distal esophagus can present with severe retrosternal chest and/or upper abdominal pain, tachypnea, dyspnea, cyanosis, fever, and shock. (See "[Overview of esophageal injury due to blunt or penetrating trauma in adults](#)", section on 'Clinical features and diagnosis' and "[Overview of gastrointestinal tract perforation](#)", section on 'Clinical features'.)

Patients with an intra-abdominal perforation often report epigastric pain that may radiate to the shoulder. Patients may also report back pain and an inability to lie supine or present with an acute (surgical) abdomen with rebound, guarding, tachycardia, hypotension, and fever. As with intrathoracic perforation, sepsis can rapidly develop within hours of presentation.

**Obstruction** — The symptoms most commonly associated with acute small bowel obstruction are nausea, vomiting, cramping abdominal pain, and obstipation (ie, inability to pass flatus or stool). (See "[Etiologies, clinical manifestations, and diagnosis of mechanical small bowel obstruction in adults](#)", section on 'Clinical presentations'.)

**Fistula** — Impaction of a foreign body in the esophagus can cause ulceration due to tissue necrosis and if prolonged can result in the formation of an aorto-esophageal or tracheo-esophageal fistula. Aorto-enteric fistulas are rare; gastrointestinal bleeding is the most common presentation. The severity of bleeding ranges from a minor hemorrhage to massive, life-threatening bleeding, or overt rapid exsanguination. Patients with a tracheo-esophageal fistula usually present with cough, cyanosis, and dysphagia, choking, and vomiting.

---

## EVALUATION

**History and examination** — The history should include the type of foreign body, the time of ingestion, and the presence and type of ongoing symptoms. Drooling and inability to swallow liquids is indicative of an esophageal obstruction and requires emergent endoscopic evaluation. Review previous episodes (if any), their frequency and severity, and prior documented

endoscopic findings or diagnoses (ie, achalasia, eosinophilic esophagitis). (See ['Esophageal foreign body'](#) below.)

Physical examination should also include an inspection of the oro- and hypopharynx, neck, chest, and abdomen to identify patients with esophageal obstruction (drooling and inability to swallow liquids), or perforation. Adults and older children can typically identify foreign body ingestion and may point to a specific area of discomfort, though the area often does not correspond with the site of impaction [28]. For patients in respiratory distress, endotracheal intubation may be required prior to endoscopy. (See ['Complications'](#) above and ['Airway management'](#) below and ["Boerhaave syndrome: Effort rupture of the esophagus"](#), section on ['Clinical manifestations'](#).)

## Imaging

**Indications and choice of modality** — Radiographic localization and identification of foreign bodies is valuable in guiding management. However, imaging is only performed in patients without signs or symptoms suggestive of a complete esophageal obstruction (drooling and inability to swallow liquids). (See ['History and examination'](#) above.)

- In adult patients with a suspected complete esophageal obstruction due to a foreign body ingestion, imaging is not mandatory and should not delay urgent endoscopy. (See ['Therapeutic upper endoscopy'](#) below and ['Symptoms'](#) above.)
- In individuals with suspected nonbony food bolus impaction without complications (eg, no clinical evidence suggestive of perforation or respiratory distress), endoscopy can be performed without imaging.
- In patients without a suspected esophageal obstruction and a history of ingestion of a radiopaque blunt foreign body or if the type of object is unknown, we perform plain radiographs. However, not all foreign bodies will be seen on radiographs. As examples, fish/chicken bones, wood, plastic, glass, thin metal objects, and food impactions are not readily seen on plain films, so failure to locate them on radiographic examination does not preclude their presence. Patients with esophageal symptoms should undergo endoscopic evaluation despite negative imaging. (See ['Symptomatic patient with negative imaging'](#) below.)

We perform a computed tomography (CT) scan for evaluation in the following clinical scenarios:

- Suspected perforation based on either clinical or radiographic findings

- Sharp or pointed foreign body ingestion
- In patients suspected of having ingested packets of narcotics or other drugs but with an unclear history. (See "[Acute ingestion of illicit drugs \(body stuffing\)](#)", section on '[Computerized tomography](#)'.)

CT scan is typically performed without oral contrast to minimize the risk of aspiration. Contrast coating the foreign body and esophageal mucosa can also interfere with endoscopic visualization. CT scans can be falsely negative if ingested foreign bodies are radiolucent.

**Radiography** — Plain radiographs (anteroposterior and lateral views from neck, chest, and abdomen) can confirm the size, shape, number, and location of a radio-opaque foreign body, but food bolus, thin metal objects, wood, plastic, and glass, and fish or chicken bones are not readily seen. In particular, identification of airway landmarks on posterior-anterior and lateral chest radiographs is important to differentiate between tracheobronchial and esophageal foreign bodies [29].

- Flat objects, such as coins, usually orient themselves in the coronal plane when lodged in the esophagus and are best seen on anteroposterior projections ( [image 1](#)). Coins have a sharp, crisp edge.
- Tracheal foreign bodies align in the sagittal plane and are best seen on a lateral projection [30] ( [image 2](#)).
- Disk batteries may be seen as a double shadow or a stack of coins, depending upon their position ( [image 3](#) and [image 4](#)).

Findings suggestive of an esophageal perforation on chest radiographs include mediastinal or free peritoneal air or subcutaneous emphysema. With cervical esophageal perforations, plain films of the neck may show air in the soft tissues of the prevertebral space. Other findings suggestive of an esophageal perforation include pleural effusions, mediastinal widening, hydrothorax, hydropneumothorax, or subdiaphragmatic air. In addition, mediastinal emphysema may not become visible radiographically after an hour of perforation and pleural effusion(s) and mediastinal widening take several hours to develop. (See "[Boerhaave syndrome: Effort rupture of the esophagus](#)", section on '[Thoracic and cervical radiography](#)'.)

**Computed tomography** — With CT, the shape, size, location, and depth of the impacted foreign body and the surrounding tissue can be visualized, which is important in determining treatment options and evaluating the risks of endoscopic management. CT not only provides

better anatomic information, but can also detect other complications (eg, abscess, mediastinitis, or aortic/tracheal fistula). (See '[Complications](#)' above.)

Multidetector CT scan has a higher sensitivity and specificity relative to radiographs (100 and 94 percent, respectively) in the detection of sharp or pointed foreign bodies in the esophagus [31].

CT scan findings consistent with an esophageal perforation include esophageal wall edema and thickening, periesophageal fluid with or without gas bubbles, mediastinal widening, and air and fluid in the pleural spaces, retroperitoneum, or lesser sac. CT scan does not allow for localization of the exact site of the esophageal perforation but is highly sensitive for detecting small amounts of extravasated contrast or air in soft tissues adjacent to the esophagus or in the mediastinum. (See "[Boerhaave syndrome: Effort rupture of the esophagus](#)", section on '[Computed tomography](#)'.)

---

## INITIAL APPROACH BASED ON CLINICAL PRESENTATION

The approach to management is guided by the initial evaluation and depends upon the following (see '[Evaluation](#)' above):

- Presence and severity of symptoms (see '[History and examination](#)' above and '[Clinical manifestations](#)' above and '[Imaging](#)' above)
- Type of object ingested (size, shape, content)
- Location of the object as determined by imaging, if performed (see '[Imaging](#)' above)

In general, conservative management is appropriate for the majority of ingestions, since most objects will pass uneventfully [10,11]. The timing of endoscopic intervention varies with the type of ingestion and the clinical setting [32,33]. (See '[Special techniques and considerations based on ingestion](#)' below.) The patient should be given a sputum collection bag and oropharyngeal suction for use as needed to prevent aspiration of accumulated secretions.

**Esophageal foreign body** — All foreign bodies in the esophagus require removal within 24 hours [5,33-35].

- **Emergent endoscopy** — Emergent (early) endoscopy (preferably within two hours, but at the latest within 12 hours) is indicated in patients with any of the following:
  - Complete esophageal obstruction as evidenced by drooling and an inability to handle oral secretions
  - Disk batteries in the esophagus
  - Sharp-pointed objects in the esophagus [13]

- **Urgent endoscopy (within 24 hours)** — Any other foreign body lodged in the esophagus should be retrieved within the 24 hours following the ingestion, because the risk of complications dramatically increases with time [13]. (See '[Complications](#)' above.)

**Foreign body in the stomach or proximal duodenum** — Most foreign bodies that enter the stomach will pass in four to six days. However, objects greater than 2 to 2.5 cm in diameter will not pass through the pylorus or ileocecal valve and objects longer than 5 to 6 cm will not pass through the duodenal sweep.

- **Early upper endoscopy in selected patients** — Urgent endoscopy (within 24 hours) is indicated in patients with any one of the following:
  - Sharp-pointed object in the stomach or duodenum
  - Objects >5 cm in length at or above the proximal duodenum
  - Magnets within endoscopic reach

Upper endoscopy (within 72 hours) is also indicated for foreign bodies in the stomach that are unlikely to pass through the gastrointestinal tract. This includes patients with any one of the following:

- Blunt objects in the stomach that are >2 cm in diameter
- Disk batteries and cylindrical batteries remaining in the stomach longer than 24 hours
- **Expectant management in other patients** – Asymptomatic patients with small (<2.5 cm in diameter and <5 cm in length), blunt objects can be managed expectantly.
  - Patients managed expectantly should undergo radiographic monitoring weekly. Patients should resume a normal diet and monitor their stools for evidence of the object. Osmotic laxatives (polyethylene glycol) may be used since they dilute the intestinal contents and facilitate intestinal transport and the identification of the foreign body in the stool after passing. An abdominal radiograph one to two days after the patient notes the object in the stool can help confirm passage, provided that the object is radiopaque.
  - Patients who fail expectant management, require upper endoscopy to retrieve the foreign body. Failure of expectant management is defined as one of the following:
    - Nonprogression of the foreign body: Foreign bodies that fail to pass through the stomach in three to four weeks or remain in the distal duodenum for more than one week
    - Development of associated symptoms (eg, abdominal pain, nausea, or vomiting)

**Foreign body distal to the ligament of Treitz** — If a foreign body cannot be retrieved endoscopically, radiographic follow-up examinations should be performed to assess the object's passage through the gastrointestinal tract. Hair and plant materials or metallic objects may cause foreign body appendicitis and perforation [36].

Deep small bowel enteroscopy has been used as an alternative to surgery for the management of patients with foreign bodies in the small bowel. (See "[Overview of deep small bowel enteroscopy](#)", section on 'Therapeutic applications'.)

**Symptomatic patient with negative imaging** — Patients with negative radiographs who are asymptomatic can be followed expectantly. Patients with persistent esophageal symptoms should undergo endoscopic evaluation, even if the radiographic examination is negative. In addition, in patients with suspected nonbony food impactions who do not have evidence of complications, endoscopy may be performed without first obtaining radiographic imaging.

---

## THERAPEUTIC UPPER ENDOSCOPY

**Airway management** — Airway protection is important for all patients undergoing endoscopic foreign body removal. Oropharyngeal suction is required to avoid pulmonary aspiration. Patients with impactions in the upper esophagus may require endotracheal intubation to protect the airway. Other potential indications for endotracheal intubation are when objects are difficult to remove, when there are multiple objects, when the duration of an esophageal foreign body impaction is unknown, and when rigid esophagoscopy is needed [33].

The use of an overtube should also be considered to prevent an object from accidentally being dropped into the patient's airway. In addition, a laryngoscope should be immediately available in the event of airway obstruction. (See '[Endoscopic tools](#)' below.)

**Choice of endoscope** — The forward-viewing flexible endoscope has become the instrument of choice in managing foreign bodies in most medical centers because it permits safe extraction of the object and inspection of the esophageal mucosa [5,15]. It can usually be performed under conscious sedation. However, patients with objects that are difficult to remove, who have ingested multiple objects, or with significant psychiatric illness may require endotracheal intubation and general anesthesia. Rigid endoscopy may be required to remove foreign bodies in the upper esophagus [37].

The use of large channel or double channel endoscopes may be advantageous over standard caliber endoscopes since they can facilitate clearance of food particles and other esophageal luminal contents proximal to the foreign body impaction. However, these larger endoscopes are



harder to navigate around the foreign body in search of underlying distal esophageal pathology and may not be readily available at all centers. As a result, some endoscopists prefer the smaller, more flexible standard esophagogastroduodenoscopes.

Both flexible and rigid endoscopic approaches are successful in more than 90 percent of cases, but rigid endoscopy is associated with a higher perforation rate as compared with flexible endoscopy [37,38]. However, the overall incidence of esophageal perforation with these techniques is low. In a series of 192 adults and children requiring foreign body extraction using rigid or flexible esophagoscopy, no serious complications (mediastinitis, hemorrhage, perforation, or death) were noted [38].

## Endoscopic tools

- **Retrieval devices** – All endoscopic manipulation should be performed under maximal esophageal distention using air insufflation. Devices that are commonly used for foreign body removal included rat-tooth and alligator forceps, polypectomy snares, baskets, and nets. The rat-tooth forceps and the snare are the most frequently used accessory devices [15]. In general, the endoscopic tools used vary with the type of foreign body:
  - Depending upon the bolus or foreign body shape, a polypectomy snare, tripod, or stone basket may be used.
  - Coins are best retrieved with a rat-tooth forceps, snare, or retrieval net.
  - Round objects such as disk or button batteries are best captured using a retrieval net [39].
- **Overtube or foreign body protector hood** – Overtubes may be used to protect the airway when removing objects that are difficult to grasp securely and to facilitate passage of the endoscope multiple times for piecemeal removal of a food bolus or to remove multiple objects. Overtubes can also be used to protect the esophageal mucosa when removing sharp objects. Overtubes are backloaded over the endoscope before the procedure and then slowly advanced with the endoscope into the esophagus (short overtubes) or into the stomach (long overtubes). In some cases, application of the overtube over a meat bolus followed by rigorous suction through the endoscope may suction the bolus into the end of the overtube and facilitate removal.

In the absence of an overtube, a foreign body protector hood should be used to protect the esophageal mucosa during removal of a sharp or pointed objects that are distal to the esophagus. (See '[Sharp-pointed objects](#)' below.)

## Special techniques and considerations based on ingestion

**Food bolus** — The bolus can be removed using grasping devices (either en bloc or piecemeal, depending upon the consistency of the bolus), or it can be gently pushed into the stomach using the endoscope [40,41]. However, excessive force must not be applied since it can result in perforation. If attempts to gently push the bolus into the stomach fail, then the bolus should be removed using a grasping device (preferably via an overtube). A friction-fit adaptor attached to the end of the endoscope can be helpful for aspirating pieces of the food bolus under direct vision [33,42,43]. The use of an endoscopic mucosal resection cap to suction and remove the entire bolus en bloc is more effective, safer, time-efficient, and less costly than the conventional approach [44].

If an esophageal stricture or ring is identified after clearing a food bolus, dilation should be performed during the same session, provided there is no significant mucosal inflammation. However, before performing dilation, eosinophilic esophagitis (EoE) should also be considered, since accumulating data suggest that up to one-half of patients presenting with food impaction have EoE [16,45,46]. Dilation should be deferred or performed extremely cautiously if eosinophilic esophagitis is suspected because of the risk of severe chest pain, mucosal tearing, and perforation [47]. (See "[Treatment of eosinophilic esophagitis \(EoE\)](#)", section on 'Esophageal dilation'.)

Administration of [glucagon](#) (1 mg IV) can be attempted to relax the esophagus, which may promote passage of the food bolus. Studies of glucagon in this setting have had mixed results, with some studies suggesting a benefit while others do not [48-51]. However, glucagon is relatively safe and is a reasonable option, provided its administration does not delay definitive endoscopic therapy.

[Budesonide](#) orodispersible tablet has been used as medical rescue therapy [52]. In one small series of eight patients with eosinophilic esophagitis, three patients had resolution of esophageal food impaction without endoscopic intervention [52].

The role of meat tenderizers (such as papain) in patients with food impactions is unclear and there is insufficient evidence to recommend their use. While there are reports of severe esophagitis due to its use, in other retrospective studies the use of papain has not been associated with other significant esophageal complications, including esophageal perforation, pneumonitis, or pneumonia [53,54].

**Blunt objects** — Blunt objects should be removed with equipment that is suited to the shape of the object. Coins, for example, are best removed with foreign body forceps (rat-tooth or alligator), a snare, or a retrieval net [5,33,34]. Smooth and round objects are more easily

removed with a retrieval net or basket [55]. Blunt objects that cannot be secured in the esophagus may be advanced into the stomach where they may be easier to grasp.

Blunt objects that have already entered the stomach can usually be managed conservatively since most will pass within four to six days (although it may take as long as four weeks) [33,56-58]. In adults, objects larger than 2.5 cm are less likely to pass the pylorus and should be removed endoscopically. Patients should consume a regular diet and observe their stools for passage of the object. Weekly radiographs are sufficient in asymptomatic patients. Endoscopic or surgical removal (depending upon the location of the object) should be considered if the object fails to pass out of the stomach within three to four weeks or if an object distal to the duodenum remains in the same location for more than one week. Surgery is also indicated in patients who develop symptoms suggestive of peritonitis, such as fever, vomiting, or abdominal pain.

The approach to patients with internal concealment of drugs of abuse (body packing) is discussed in detail separately. (See "[Internal concealment of drugs of abuse \(body packing\)](#)", [section on 'Treatment'](#).)

**Long objects** — Long objects (longer than 5 cm) are unlikely to pass the duodenal sweep and should be removed [10,33,59]. Examples include toothbrushes and spoons. The objects can be grasped with a snare or basket and drawn into a long overtube (ie, >45 cm), after which the entire apparatus can be withdrawn in one motion [33].

**Sharp-pointed objects** — The presence of sharp-pointed objects (such as chicken and fish bones, straightened paper clips, toothpicks, needles, bread-bag clips, and dental bridgework) in the esophagus represents a medical emergency because of the risk of perforation. While sharp-pointed objects that enter the stomach often pass uneventfully through the remainder of the gastrointestinal tract, complications have been described in up to 35 percent of patients [8]. Thus, they should be removed endoscopically if possible [5,8,60]. The longer the duration of the impaction prior to endoscopy and the longer the diameter of the foreign body, the higher the risk of perforation [61].

Endoscopic management may be difficult if the foreign body pierces the esophageal wall and becomes impacted. Impacted foreign bodies, typically poultry or fish bones, should be treated as early as possible, and their endoscopic management is generally safe and effective. Endoscopic management is the first choice for perforating foreign bodies when the duration of impaction is less than 24 hours and there are no abscesses outside of the esophageal tract or signs of esophageal perforation (eg, pneumomediastinum) seen on a computed tomography scan [62]. Surgical treatment is typically required if an abscess has developed or if there are

signs of esophageal perforation. If a foreign body has been impacted for >24 hours and there is no abscess/free air, endoscopic retrieval should be attempted first and management individualized based on the findings (see '[Management of complications](#)' below). Odynophagia at the site of previous sharp foreign body impaction may persist for several days after endoscopic removal. If not improving, re-endoscopy to search for residual perforating broken bony particles should be considered.

For removal of sharp objects in the stomach, a protector hood should be placed at the tip of the endoscope, or a long overtube that spans the esophagogastric junction should be inserted [63]. The bell portion of the flexible endoscopic protector hood is inverted during insertion of the endoscope. The object is then grasped, and the scope is withdrawn. If only one end of the object is pointed, when possible, the object should be grasped so that the sharp end is trailing during removal (ie, pointing away from the endoscope). When the protector hood comes into contact with the esophagogastric junction during withdrawal, the hood is pushed forward, forming a bell that surrounds the tip of the endoscope and the object, protecting the esophageal and pharyngeal mucosa from any sharp edges.

If endoscopic removal of a sharp-pointed object in the esophagus cannot be achieved safely, patients should be followed with daily radiographs; surgical removal should be considered for objects that do not advance within three consecutive days or in patients who develop abdominal pain, vomiting, fevers, hematemesis, or melena [33]. (See '[Failed or unfeasible endoscopic retrieval](#)' below.)

**Disk batteries** — Batteries less than 15 mm in diameter almost never lodge in the esophagus [64]. Disk batteries in the esophagus should be removed promptly. Contact of the flat esophageal wall with both poles of the battery conducts electricity that may rapidly result in liquefaction necrosis and perforation [65,66]. Identification of the type of battery and its active components and mechanism of injury are discussed in detail separately. (See "[Button and cylindrical battery ingestion: Clinical features, diagnosis, and initial management](#)", section on '[Battery description](#)'.)

These batteries can be removed with a retrieval basket or net. An alternative technique involves inserting a balloon under direct visualization past the battery, after which it is inflated and then withdrawn to capture the battery between the balloon and the tip of the endoscope [33]. The balloon, battery, and endoscope can then be removed as one unit. With this type of retrieval method, there is a risk of the battery falling into the trachea, so an overtube **must** be used to protect the airway. If the battery is retrieved by securely capturing it within a retrieval net, an overtube is not required. A battery that cannot be removed from the esophagus can be gently advanced into the stomach where retrieval is sometimes easier.

Most disk batteries that are in the stomach will subsequently pass through the remaining gastrointestinal tract without consequence. Patients who present with the disk battery in the stomach can be followed with a radiograph every three to four days; 85 percent pass within 72 hours once the battery is beyond the duodenal sweep [67]. Endoscopic removal should be attempted in patients who develop signs or symptoms of gastrointestinal tract injury, those who have ingested batteries larger than 20 mm in diameter, and those in whom the battery remains in the stomach for longer than 48 hours.

**Magnets** — Ingested magnets may result in severe gastrointestinal injury because the attractive force between magnets or between a magnet and an ingested metal object can trap a portion of the bowel wall and cause necrosis. This can result in fistula formation, perforation, obstruction, volvulus, or peritonitis [68]. While patients who only report ingestion of one magnet may not be at risk, if additional undetected magnets or pieces of metal were ingested along with the magnet, damage could occur. Younger age and ingestion of greater numbers of multiple magnets are independently associated with surgery. As a result, all magnets within endoscopic reach should be removed if possible [69,70].

**Additional interventions** — Laxatives may expedite passage through the gastrointestinal tract and can be used to decrease transit time [71]. However, emetics should not be used due to the risk of aspiration. The role of acid suppression has not been established.

Biopsies of the distal and proximal/mid-esophagus should be obtained to evaluate for eosinophilic esophagitis. In the absence of significant mucosal injury, underlying structural defects, such as strictures or a Schatzki ring, should be dilated. Patients undergoing esophageal dilation for the first time may require multiple sessions, especially if the stricture has a narrow diameter and exhibits significant resistance during dilation. (See "[Clinical manifestations and diagnosis of eosinophilic esophagitis \(EoE\)](#)", section on 'Endoscopy' and "[Esophageal rings and webs](#)", section on 'Management'.)

---

## SUBSEQUENT MANAGEMENT

**Following successful endoscopic retrieval** — Patients with foreign body ingestion or food bolus impaction can usually be treated as outpatients after endoscopic therapy.

Indications for hospitalization following successful endoscopic retrieval of a foreign body include:

- Ingestion of multiple objects or foreign bodies associated with a high risk for complications (ie, sharp-pointed objects, batteries, magnets, objects longer than 5 cm)

- Extensive mucosal injury due to the foreign body ingestion or endoscopic extraction

**Failed or unfeasible endoscopic retrieval** — If a foreign body cannot be retrieved endoscopically, daily radiographic follow-up examinations should be performed to assess the object's passage through the gastrointestinal tract.

Inpatient management with close observation (clinical and radiographic) is indicated for sharp pointed objects, batteries and magnets. Surgery is indicated in patients who develop complications (eg, obstruction, perforation) and for nonprogression of a foreign body (a blunt object that remains in the same location distal to the duodenum for more than one week or a sharp foreign body that does not advance radiographically for three consecutive days). (See ['Management of complications'](#) below.)

**Prevention of recurrence** — Recurrent esophageal foreign body impactions occur in 10 to 20 percent of cases. An upper endoscopy should be performed to evaluate mucosal healing in patients with extensive mucosal injury on initial endoscopy. An upper endoscopy is also indicated to biopsy the esophagus for eosinophilic esophagitis and manage underlying structural defects (eg, dilation of strictures or a Schatzki ring), if not concurrently performed at the time of the initial endoscopy. Readmissions due to eosinophilic esophagitis are more likely to occur in the first 10 days of discharge and at a lesser rate when upper endoscopy and dilation are performed at the index admission [72].

Patients without structural abnormalities should also be evaluated for an esophageal motility disorder [33,73,74]. (See ["Endoscopic interventions for nonmalignant esophageal strictures in adults"](#) and ["Distal esophageal spasm and hypercontractile esophagus"](#) and ["Esophageal rings and webs"](#), section on ["Management"](#).)

---

## MANAGEMENT OF COMPLICATIONS

Management of complications including obstruction, perforation and aorto-esophageal or trachea-esophageal fistulae are discussed in detail separately. (See ["Complications of endoscopic esophageal stricture dilation"](#), section on ["Patient selection for medical management"](#) and ["Management of small bowel obstruction in adults"](#) and ["Tracheo- and broncho-esophageal fistulas in adults"](#), section on ["Management and outcomes"](#).)

---

## SOCIETY GUIDELINE LINKS

Links to society and government-sponsored guidelines from selected countries and regions around the world are provided separately. (See "[Society guideline links: Esophageal strictures, foreign bodies, and caustic injury](#)".)

---

## INFORMATION FOR PATIENTS

UpToDate offers two types of patient education materials, "The Basics" and "Beyond the Basics." The Basics patient education pieces are written in plain language, at the 5<sup>th</sup> to 6<sup>th</sup> grade reading level, and they answer the four or five key questions a patient might have about a given condition. These articles are best for patients who want a general overview and who prefer short, easy-to-read materials. Beyond the Basics patient education pieces are longer, more sophisticated, and more detailed. These articles are written at the 10<sup>th</sup> to 12<sup>th</sup> grade reading level and are best for patients who want in-depth information and are comfortable with some medical jargon.

Here are the patient education articles that are relevant to this topic. We encourage you to print or e-mail these topics to your patients. (You can also locate patient education articles on a variety of subjects by searching on "patient info" and the keyword(s) of interest.)

- Basics topics (see "[Patient education: Upper endoscopy \(The Basics\)](#)" and "[Patient education: Swallowed objects \(The Basics\)](#)")
  - Beyond the Basics topics (see "[Patient education: Upper endoscopy \(Beyond the Basics\)](#)")
- 

## SUMMARY AND RECOMMENDATIONS

- Foreign body ingestion is rare in adults and is usually accidental. Most (80 to 90 percent) ingested foreign bodies pass without the need for intervention. Endoscopic intervention is required in 10 to 20 percent of patients, and surgical intervention is required in less than 1 percent. The esophagus is the most frequent site of obstruction in the gastrointestinal tract. Esophageal foreign bodies and food are often impacted at sites of physiologic or pathologic luminal narrowing ( [table 1](#)). (See '[Epidemiology](#)' above.)
- The typical clinical presentation is the acute onset of dysphagia. Other symptoms of esophageal foreign body impaction include choking, refusal to eat, hypersalivation, retrosternal fullness, regurgitation of undigested food, wheezing, and blood-stained saliva. Drooling and inability to swallow liquids is indicative of an esophageal obstruction. Complications of foreign body ingestion include perforation, obstruction, aorto-esophageal

fistula formation, and tracheoesophageal fistula formation. (See '[Clinical manifestations](#)' above.)

- The history should include the type of foreign body, the time of ingestion, and the presence and type of ongoing symptoms. Drooling and inability to swallow liquids is indicative of an esophageal obstruction and requires emergent endoscopic evaluation. Physical examination should include an inspection of the oro- and hypopharynx, neck, chest, and abdomen to identify patients with ongoing symptoms of esophageal obstruction (drooling and inability to swallow liquids) or perforation. (See '[History and examination](#)' above.)
- Imaging is only performed in patients without signs or symptoms suggestive of an esophageal obstruction. In patients without a suspected esophageal obstruction and a history of ingestion of a radiopaque blunt foreign body or if the type of object is unknown, we perform plain radiographs. We perform a computed tomography scan for evaluation in the following clinical scenarios:
  - Suspected perforation based on either clinical or radiographic findings
  - Sharp or pointed foreign body ingestion
  - In patients suspected of having ingested packets of narcotics or other drugs but with an unclear history (See '[Imaging](#)' above.)
- Radiographic localization and identification of foreign bodies can guide management. However, failure to locate an object on radiographic examination does not preclude its presence. In patients with suspected nonbony food impactions who do not have evidence of complications, endoscopy may be performed without first obtaining radiographic imaging. In patients with persistent esophageal symptoms, an endoscopic evaluation should be performed, even if the radiographic examination is negative. (See '[Evaluation](#)' above.)
- The approach to management depends upon the following:
  - Type of object ingested (size, shape, content)
  - Location of the object
  - Presence and severity of symptoms

In general, conservative management is appropriate for the majority of foreign body ingestions, since most objects will pass uneventfully. The timing of endoscopic intervention varies with the type of ingestion and the clinical setting. (See '[Initial approach](#)



based on clinical presentation' above and 'Therapeutic upper endoscopy' above and 'Special techniques and considerations based on ingestion' above.)

- All foreign bodies in the esophagus require removal within 24 hours. Most foreign bodies that enter the stomach will pass in four to six days, and conservative management is appropriate for most blunt objects in asymptomatic patients. Endoscopic intervention is required for sharp-pointed object, magnets, blunt objects >5 cm length or >2 cm in diameter, and disk batteries remaining in the stomach longer than 24 hours. (See 'Initial approach based on clinical presentation' above.)
- Patients with foreign body ingestion or food bolus impaction can usually be treated as outpatients after endoscopic therapy. Indications for hospitalization following successful endoscopic retrieval of a foreign body include:
  - Ingestion of multiple objects or foreign bodies associated with a high risk for complications (ie, sharp-pointed objects, batteries, magnets, objects longer than 5 cm)
  - Extensive mucosal injury due to the foreign body ingestion or endoscopic extraction (see 'Following successful endoscopic retrieval' above)
- If a foreign body cannot be retrieved endoscopically, daily radiographs should be performed to assess the object's passage through the gastrointestinal tract. Surgery is reserved for patients who develop complications (eg, obstruction, perforation) and for nonprogression of a foreign body (a blunt object that remains in the same location distal to the duodenum for more than one week or a sharp foreign body that does not advance radiographically for three consecutive days). (See 'Subsequent management' above.)
- Recurrent esophageal foreign body impactions occur in 10 to 20 percent of cases. An upper endoscopy should be performed to evaluate mucosal healing in patients with extensive mucosal injury on initial endoscopy. An upper endoscopy is also indicated to biopsy the esophagus for eosinophilic esophagitis and manage underlying structural defects (eg, dilation of strictures or a Schatzki ring), if not concurrently performed at the time of the initial endoscopy. Patients without structural abnormalities should be evaluated for an esophageal motility disorder. (See 'Prevention of recurrence' above.)

Use of UpToDate is subject to the [Terms of Use](#).

## REFERENCES

1. ASGE Standards of Practice Committee, Ikenberry SO, Jue TL, et al. Management of ingested foreign bodies and food impactions. *Gastrointest Endosc* 2011; 73:1085.
2. Birk M, Bauerfeind P, Deprez PH, et al. Removal of foreign bodies in the upper gastrointestinal tract in adults: European Society of Gastrointestinal Endoscopy (ESGE) Clinical Guideline. *Endoscopy* 2016; 48:489.
3. Schunk JE, Harrison AM, Corneli HM, Nixon GW. Fluoroscopic foley catheter removal of esophageal foreign bodies in children: experience with 415 episodes. *Pediatrics* 1994; 94:709.
4. Wu WT, Chiu CT, Kuo CJ, et al. Endoscopic management of suspected esophageal foreign body in adults. *Dis Esophagus* 2011; 24:131.
5. Webb WA. Management of foreign bodies of the upper gastrointestinal tract: update. *Gastrointest Endosc* 1995; 41:39.
6. Sheth P, Finkelstein E, Campbell D, Danton GH. Imaging of foreign bodies in prisoners. *Semin Ultrasound CT MR* 2015; 36:28.
7. Ribas Y, Ruiz-Luna D, Garrido M, et al. Ingested foreign bodies: do we need a specific approach when treating inmates? *Am Surg* 2014; 80:131.
8. Vizcarrondo FJ, Brady PG, Nord HJ. Foreign bodies of the upper gastrointestinal tract. *Gastrointest Endosc* 1983; 29:208.
9. Wisniewski RM, Stone DD, Fang JC. An esophageal foreign body impaction from a Tums E-X tablet. *Gastrointest Endosc* 1997; 45:518.
10. Pellerin D, Fortier-Beaulieu M, Guegen J. The fate of swallowed foreign bodies: Experience of 1250 instances of subdiaphragmatic foreign bodies in children. *Program Pediatr Radiol* 1969; 2:302.
11. Carp L. FOREIGN BODIES IN THE INTESTINE. *Ann Surg* 1927; 85:575.
12. Liu Q, Liu F, Xie H, et al. Emergency Removal of Ingested Foreign Bodies in 586 Adults at a Single Hospital in China According to the European Society of Gastrointestinal Endoscopy (ESGE) Recommendations: A 10-Year Retrospective Study. *Med Sci Monit* 2022; 28:e936463.
13. Yadollahi S, Buchannan R, Tehami N, et al. Endoscopic management of intentional foreign body ingestion: experience from a UK centre. *Frontline Gastroenterol* 2022; 13:98.
14. Weiland ST, Schurr MJ. Conservative management of ingested foreign bodies. *J Gastrointest Surg* 2002; 6:496.
15. Li ZS, Sun ZX, Zou DW, et al. Endoscopic management of foreign bodies in the upper-GI tract: experience with 1088 cases in China. *Gastrointest Endosc* 2006; 64:485.

16. Desai TK, Stecevic V, Chang CH, et al. Association of eosinophilic inflammation with esophageal food impaction in adults. *Gastrointest Endosc* 2005; 61:795.
17. Nandi P, Ong GB. Foreign body in the oesophagus: review of 2394 cases. *Br J Surg* 1978; 65:5.
18. Khan MA, Hameed A, Choudhry AJ. Management of foreign bodies in the esophagus. *J Coll Physicians Surg Pak* 2004; 14:218.
19. Adams DB. Endoscopic removal of entrapped coins from an intraluminal duodenal diverticulum 20 years after ingestion. *Gastrointest Endosc* 1986; 32:415.
20. Kirberg AE. Long-standing esophageal foreign body. *Gastrointest Endosc* 1986; 32:304.
21. Yamamoto M, Mizuno H, Sugawara Y. A chopstick is removed after 60 years in the duodenum. *Gastrointest Endosc* 1985; 31:51.
22. Tsui BC, Mossey J. Occult liver abscess following clinically unsuspected ingestion of foreign bodies. *Can J Gastroenterol* 1997; 11:445.
23. Zhang X, Liu J, Li J, et al. Diagnosis and treatment of 32 cases with aortoesophageal fistula due to esophageal foreign body. *Laryngoscope* 2011; 121:267.
24. Ahn D, Heo SJ, Park JH, Sohn JH. Tracheoesophageal fistula with tracheal stenosis resulting from retained esophageal foreign body. *Auris Nasus Larynx* 2011; 38:753.
25. Sung SH, Jeon SW, Son HS, et al. Factors predictive of risk for complications in patients with oesophageal foreign bodies. *Dig Liver Dis* 2011; 43:632.
26. Tonkic A, Kulic D, Peric M, et al. Bacteremia caused by a swallowed toothpick impacted in the gastric mucosa. *Case Rep Gastroenterol* 2011; 5:227.
27. Lam HC, Woo JK, van Hasselt CA. Management of ingested foreign bodies: a retrospective review of 5240 patients. *J Laryngol Otol* 2001; 115:954.
28. Connolly AA, Birchall M, Walsh-Waring GP, Moore-Gillon V. Ingested foreign bodies: patient-guided localization is a useful clinical tool. *Clin Otolaryngol Allied Sci* 1992; 17:520.
29. Guelfguat M, Kaplinskiy V, Reddy SH, DiPoce J. Clinical guidelines for imaging and reporting ingested foreign bodies. *AJR Am J Roentgenol* 2014; 203:37.
30. Ghahremani GG. Foreign bodies of the alimentary tract. In: *Textbook of Gastrointestinal Radiology*, Gore RM, Levine MS, Laufer I (Eds), WB Saunders, Philadelphia 1994. p.2547.
31. Ma J, Kang DK, Bae JI, et al. Value of MDCT in diagnosis and management of esophageal sharp or pointed foreign bodies according to level of esophagus. *AJR Am J Roentgenol* 2013; 201:W707.

32. Fung BM, Sweetser S, Wong Kee Song LM, Tabibian JH. Foreign object ingestion and esophageal food impaction: An update and review on endoscopic management. *World J Gastrointest Endosc* 2019; 11:174.
33. Eisen GM, Baron TH, Dominitz JA, et al. Guideline for the management of ingested foreign bodies. *Gastrointest Endosc* 2002; 55:802.
34. Ginsberg GG. Management of ingested foreign objects and food bolus impactions. *Gastrointest Endosc* 1995; 41:33.
35. Chaikhouni A, Kratz JM, Crawford FA. Foreign bodies of the esophagus. *Am Surg* 1985; 51:173.
36. Fuller MY, Leino DG, Reyes-Múgica M, et al. Ingested Foreign Bodies Can Cause Appendicitis and Perforation: A Multi-Institutional Case Series. *Pediatr Dev Pathol* 2022; 25:499.
37. Gmeiner D, von Rahden BH, Mecco C, et al. Flexible versus rigid endoscopy for treatment of foreign body impaction in the esophagus. *Surg Endosc* 2007; 21:2026.
38. Berggreen PJ, Harrison E, Sanowski RA, et al. Techniques and complications of esophageal foreign body extraction in children and adults. *Gastrointest Endosc* 1993; 39:626.
39. Neustater B, Barkin JS. Extraction of an esophageal food impaction with a Roth retrieval net. *Gastrointest Endosc* 1996; 43:66.
40. Vicari JJ, Johanson JF, Frakes JT. Outcomes of acute esophageal food impaction: success of the push technique. *Gastrointest Endosc* 2001; 53:178.
41. Longstreth GF, Longstreth KJ, Yao JF. Esophageal food impaction: epidemiology and therapy. A retrospective, observational study. *Gastrointest Endosc* 2001; 53:193.
42. Saeed ZA, Michaletz PA, Feiner SD, et al. A new endoscopic method for managing food impaction in the esophagus. *Endoscopy* 1990; 22:226.
43. Pezzi JS, Shiau YF. A method for removing meat impactions from the esophagus. *Gastrointest Endosc* 1994; 40:634.
44. Ooi M, Duong T, Holman R, et al. Comparison of Cap-Assisted vs Conventional Endoscopic Technique for Management of Food Bolus Impaction in the Esophagus: Results of a Multicenter Randomized Controlled Trial. *Am J Gastroenterol* 2021; 116:2235.
45. Kerlin P, Jones D, Remedios M, Campbell C. Prevalence of eosinophilic esophagitis in adults with food bolus obstruction of the esophagus. *J Clin Gastroenterol* 2007; 41:356.
46. Kirchner GI, Zuber-Jerger I, Endlicher E, et al. Causes of bolus impaction in the esophagus. *Surg Endosc* 2011; 25:3170.

47. Rajagopalan J, Triadafilopoulos G. Ring(s)-related esophageal meat bolus impaction: biopsy first, dilate later. *Dis Esophagus* 2009; 22:E14.
48. Ferrucci JT Jr, Long JA Jr. Radiologic treatment of esophageal food impaction using intravenous glucagon. *Radiology* 1977; 125:25.
49. Trenkner SW, Maglinte DD, Lehman GA, et al. Esophageal food impaction: treatment with glucagon. *Radiology* 1983; 149:401.
50. Tibbling L, Bjorkhoel A, Jansson E, Stenkvist M. Effect of spasmolytic drugs on esophageal foreign bodies. *Dysphagia* 1995; 10:126.
51. Sodeman TC, Harewood GC, Baron TH. Assessment of the predictors of response to glucagon in the setting of acute esophageal food bolus impaction. *Dysphagia* 2004; 19:18.
52. Schreiner P, Greuter T, Tatu A, et al. Is There a Role for Topical Swallowed Steroids upon Emergency Room Admission for Suspected Food Bolus Obstruction in Eosinophilic Esophagitis? *Dysphagia* 2022; 37:933.
53. Goldner F, Danley D. Enzymatic digestion of esophageal meat impaction. A study of Adolph's Meat Tenderizer. *Dig Dis Sci* 1985; 30:456.
54. Morse CR, Wang H, Donahue DM, et al. Use of Proteolytic Enzymes in the Treatment of Proteinaceous Esophageal Food Impaction. *J Emerg Med* 2016; 50:183.
55. Faigel DO, Stotland BR, Kochman ML, et al. Device choice and experience level in endoscopic foreign object retrieval: an in vivo study. *Gastrointest Endosc* 1997; 45:490.
56. Panieri E, Bass DH. The management of ingested foreign bodies in children--a review of 663 cases. *Eur J Emerg Med* 1995; 2:83.
57. Hachimi-Idrissi S, Corne L, Vandenplas Y. Management of ingested foreign bodies in childhood: our experience and review of the literature. *Eur J Emerg Med* 1998; 5:319.
58. Stringer MD, Capps SN. Rationalising the management of swallowed coins in children. *BMJ* 1991; 302:1321.
59. Blaho KE, Merigian KS, Winbery SL, et al. Foreign body ingestions in the Emergency Department: case reports and review of treatment. *J Emerg Med* 1998; 16:21.
60. Selivanov V, Sheldon GF, Cello JP, Crass RA. Management of foreign body ingestion. *Ann Surg* 1984; 199:187.
61. Li G, Wu D, Zhou L, et al. Delayed Endoscopic Management of Esophageal Sharp-Pointed Food Impaction: An Analysis of 829 Cases in China. *Dig Dis Sci* 2022; 67:3166.
62. Chen T, Wu HF, Shi Q, et al. Endoscopic management of impacted esophageal foreign bodies. *Dis Esophagus* 2013; 26:799.

63. Bertoni G, Pacchione D, Sassatelli R, et al. A new protector device for safe endoscopic removal of sharp gastroesophageal foreign bodies in infants. *J Pediatr Gastroenterol Nutr* 1993; 16:393.
64. Yardeni D, Yardeni H, Coran AG, Golladay ES. Severe esophageal damage due to button battery ingestion: can it be prevented? *Pediatr Surg Int* 2004; 20:496.
65. Litovitz T, Schmitz BF. Ingestion of cylindrical and button batteries: an analysis of 2382 cases. *Pediatrics* 1992; 89:747.
66. Gordon AC, Gough MH. Oesophageal perforation after button battery ingestion. *Ann R Coll Surg Engl* 1993; 75:362.
67. Litovitz TL. Battery ingestions: product accessibility and clinical course. *Pediatrics* 1985; 75:469.
68. Centers for Disease Control and Prevention (CDC). Gastrointestinal injuries from magnet ingestion in children--United States, 2003-2006. *MMWR Morb Mortal Wkly Rep* 2006; 55:1296.
69. Paediatric Surgery Trainee Research Network. Magnet and button battery ingestion in children: multicentre observational study of management and outcomes. *BJS Open* 2022; 6.
70. Thakkar H, Burnand KM, Healy C, et al. Foreign body ingestion in children: a magnet epidemic within a pandemic. *Arch Dis Child* 2021; 106:1240.
71. Namasivayam S. Button battery ingestion: a solution to a management dilemma. *Pediatr Surg Int* 1999; 15:383.
72. Srinivasan S, Sundaram S, Kennedy KF, et al. Trends and predictors of 30-day readmissions in subjects with eosinophilic esophagitis: results from a national cohort. *Dis Esophagus* 2022; 35.
73. Prasad GA, Reddy JG, Boyd-Enders FT, et al. Predictors of recurrent esophageal food impaction: a case-control study. *J Clin Gastroenterol* 2008; 42:771.
74. Breumelhof R, Van Wijk HJ, Van Es CD, Smout AJ. Food impaction in nutcracker esophagus. *Dig Dis Sci* 1990; 35:1167.

Topic 2271 Version 27.0

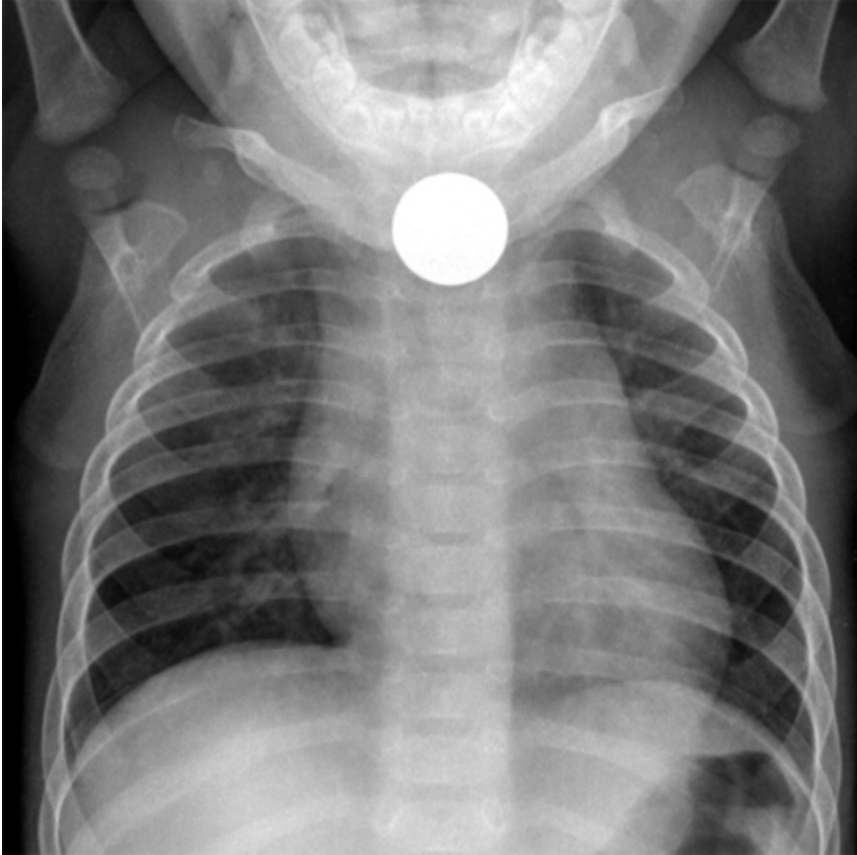## GRAPHICS

### Location of, and predisposing factors for, foreign bodies in the esophagus

Location	Frequency	Predisposing condition
Proximal one-third	Rare	Central nervous system lesions
		Zenker's diverticulum
		Cervical web
Middle one-third	Frequent	Cancer (primary or extrinsic)
		Eosinophilic esophagitis
		Radiation stricture
		Traction esophageal diverticula
		Spastic dysmotility
Distal one-third	Common	Peptic stricture
		Eosinophilic esophagitis
		Esophageal mucosal ring
		Cancer
		Achalasia
		Pulsion esophageal diverticula
		Spastic dysmotility

Graphic 66623 Version 2.0

## Esophageal foreign body



The posteroanterior chest film demonstrates a coin in the esophagus. Deviation of the trachea as a result is also noted.

---

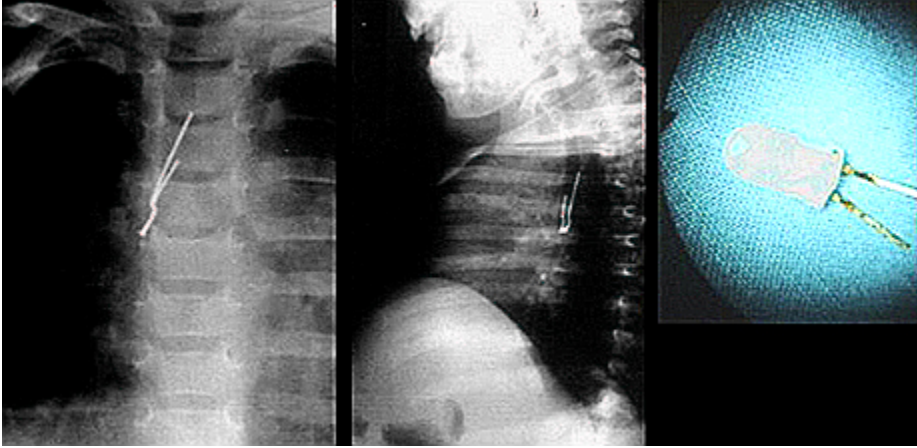
*Courtesy of Alan E Schlesinger, MD, Department of Radiology, Baylor College of Medicine.*

---

Graphic 76887 Version 3.0



## Radiopaque foreign body in the airway



Radiopaque foreign body retrieved from the airway of a 1-year-old child.

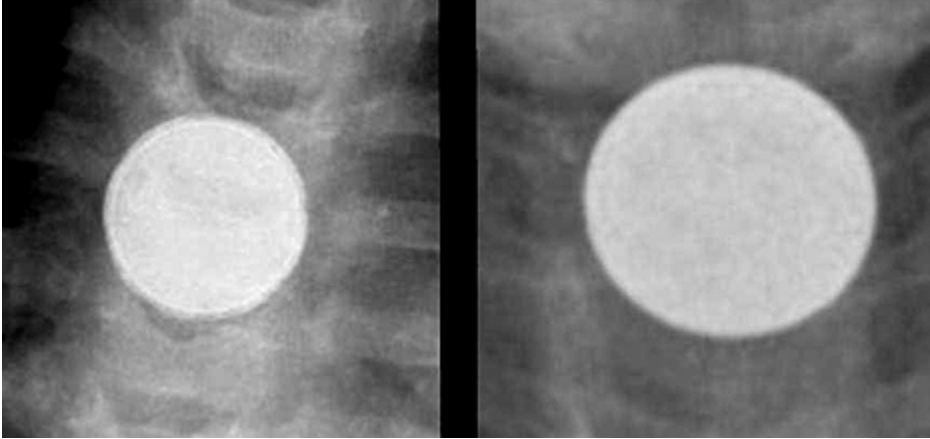
---

*Courtesy of Charles Marquette, MD.*

---

Graphic 70775 Version 5.0

## Battery versus coin ingestion



Enlarged radiographic comparison between the camera battery ingestion (left) and the coin ingestion (right) will show the subtle but characteristic differences between the two foreign bodies. The bilaminar structure of the button battery gives it a double-ring or halo appearance on plain radiograph, whereas the appearance of the coin is homogeneous.

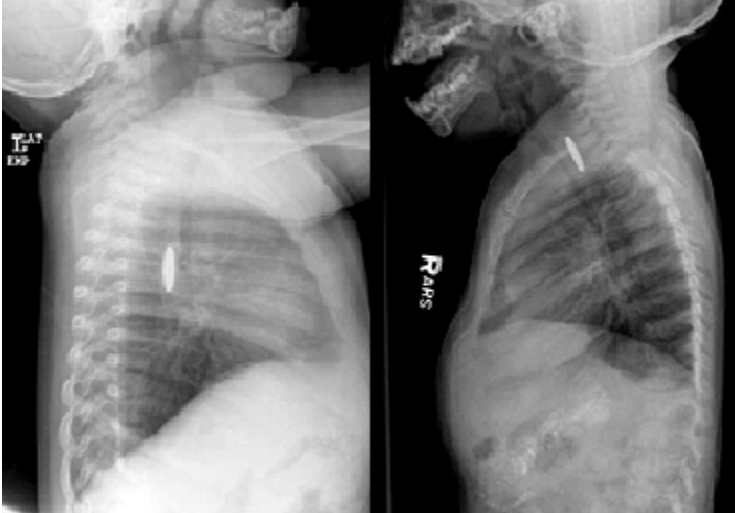
---

*Courtesy of Barbara Specter, MD.*

---

Graphic 62847 Version 3.0

## Battery versus coin ingestion



Enlarged radiographic comparison between a camera battery (left) and coin (right) demonstrates the subtle but characteristic differences of these esophageal foreign bodies. The bilaminar structure of the battery gives a "step off" appearance on the lateral view, whereas the coin has sharp, crisp edges.

---

*Courtesy of Barbara Specter, MD.*

---

Graphic 77690 Version 4.0

## Contributor Disclosures

**George Triadafilopoulos, MD** Consultant/Advisory Boards: Pentax/C2 Therapeutics [Barrett's esophagus]. All of the relevant financial relationships listed have been mitigated. **John R Saltzman, MD, FACP, FACG, FASGE, AGAF** No relevant financial relationship(s) with ineligible companies to disclose. **Shilpa Grover, MD, MPH, AGAF** No relevant financial relationship(s) with ineligible companies to disclose.

Contributor disclosures are reviewed for conflicts of interest by the editorial group. When found, these are addressed by vetting through a multi-level review process, and through requirements for references to be provided to support the content. Appropriately referenced content is required of all authors and must conform to UpToDate standards of evidence.

[Conflict of interest policy](#)

→